



SRO-MAIN CAMPUS
401 BICENTENNIAL WAY
SANTA ROSA CA 95403-
2149
Encounter Record

Hardeman, Edwin
MRN: [REDACTED], DOB: [REDACTED] Sex: M
Encounter date: 6/20/2007

Office Visit
6/20/2007

Visit Information

Date & Time	Provider	Department	Encounter #
6/20/2007 9:00 AM	Ruffner-Statzer, Susan Marie (M.D.)	GASTROENTEROLOGY	870934150

Diagnoses

CIRRHOSIS OF LIVER - Primary
HEPATITIS C, CHRONIC
HYPERTENSION

Comments

Encounter Messages

No messages in this encounter

Patient Secure Message

No messages in this encounter

Progress Notes

Progress Notes signed by Ruffner-Statzer, Susan Marie (M.D.) at 6/20/2007 9:18 AM

Version 1 of 1

Author: Ruffner-Statzer, Susan Marie (M.D.) Service: (none) Author Type: Physician
 Filed: 6/20/2007 9:32 AM Creation Time: 6/20/2007 9:18 AM Status: Signed
 Editor: Ruffner-Statzer, Susan Marie (M.D.) (Physician)
 Edwin Hardeman is a 57 Y male with +HCV, genotype 2b and cirrhosis, Biopsy not done--splenomegaly & thrombocytopenia. Treated with pegasys 180mcg weekly + Ribavirin 4/day (800mg) starting 12/2/05-11/06. TMA negative 1/07

No alcohol x 2 years, + weight loss, feeling better than before treatment.

Most recent ultrasound 1/07 neg for HCC
0058835901/10/200708:46:58RPKX0101
** FINDINGS **:

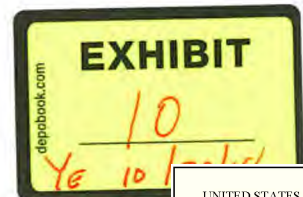
The liver has a coarsened appearance. There is no evidence of discrete mass or biliary dilatation. The common hepatic duct measures 2.8 mm. There are several polyps within the gallbladder, the largest of which measures 9.6 mm. The pancreas is normal. There is a right renal cyst measuring 2.5 cm and a left renal cyst measuring 2.7 cm. Splenomegaly is identified with a craniocaudad dimension of 14.2 cm.

O: NAD, AF, BP 126/80 | Ht 5' 10" | Wt 187 lbs (84.823 kg)
 Neck: supple, no adenop/thyromeg
 Lungs: clear
 COR: RRR no murmur, S3, S4
 ABD: NABS, soft, No HSM, no ascites,
 Skin: scattered annular scaly rash, no jaundice, no c/c/e

ASSESSMENT:

Hepatitis C
 Cirrhosis
 Antiviral therapy: completed--neg VL by TMA at 1 year post treatment
 Hypertension--on HCTZ 1 + Lisinopril well controlled

Plan:
 F/u PCP regarding HTN



UNITED STATES DISTRICT COURT
NORTHERN DISTRICT OF CALIFORNIA
TRIAL EXHIBIT 41
Case No. 3:16-cv-0525-VC
Date Entered _____
By _____
Deputy Clerk



SRO-MAIN CAMPUS
401 BICENTENNIAL WAY
SANTA ROSA CA 95403-
2149
Encounter Record

Hardeman, Edwin
MRN: [REDACTED] DOB: [REDACTED] Sex: M
Encounter date: 6/20/2007

Progress Notes (continued)

Progress Notes signed by Ruffner-Statzer, Susan Marie (M.D.) at 6/20/2007 9:18 AM (continued)

Version 1 of 1

Lab & US - HCC surveillance ordered for 7/18/07, f/u q 6 months.

Electronically signed by Ruffner-Statzer, Susan Marie (M.D.) on 6/20/2007 9:32 AM

Vitals

BP	Ht	Wt
126/80	5' 9.5"	84.8 kg (187 lb)